

# Hemi-Hamate Autograft Arthroplasty for the Proximal Interphalangeal Joint Revisited: A New Surgical Approach

Patrick K.Y. Goon\*, Kalpesh R. Vaghela<sup>†</sup>, Shirley Stougie<sup>‡</sup>, Jan H. Coert<sup>‡</sup>

*\*Department of Hand Surgery, Lister Hospital, Stevenage,*

*†Department of Trauma & Orthopaedics, Percivall Pott Rotation, Royal London Hospital, London, UK,*

*‡Department of Plastic Surgery, Erasmus MC, Rotterdam, The Netherlands*

The hemi-hamate arthroplasty for proximal interphalangeal joint (PIPJ) dorsal fracture dislocations relies on complete dislocation of the joint using the 'shotgun' approach which provides excellent exposure but damages the delicate intrinsic joint stabilisers. We present a new approach to the PIPJ when performing the hemi-hamate arthroplasty. The volar surgical approach involves freeing up the whole tendon sheath-periosteal unit as a single layer, and retracting this to one side. The articular surface of the joint can then be accessed with a little distraction and hyperextension. The method does not breach the tendon sheath, nor does it damage the collateral ligaments or volar plate. It is akin to the radical total anterior teno-arthrolysis (TATA) technique used for contracted joints, with some crucial differences. We postulate that the new approach causes far less iatrogenic damage and reduces the risk of contractures developing, and in chronic cases, allows concurrent joint release.

**Keywords:** *Autograft, Arthroplasty, Hemi-hamate, Interphalangeal joint*

## INTRODUCTION

Hemi-hamate autograft reconstruction of the middle phalanx base is an established technique that restores joint congruity after unstable fracture dislocations of the proximal interphalangeal joint (PIPJ). The matched autograft replaces the damaged volar lip of the middle phalanx, thereby reconstituting the cup-shaped contour of the phalangeal base and restoring stability. The original description of the technique involved a palmar approach and a hyperextension-dislocation ('shot-gunning') manoeuvre of the PIPJ. This approach provides an unparalleled view of the damaged joint but necessitates damage to stabilising structures such as the volar plate

and collateral ligaments, which inevitably contributes to post-operative joint stiffness and contracture. We report on our experience utilising a novel approach to the joint that does not involve 'shot-gunning'. The study was conducted in accordance with the Strengthening the Reporting of Observational Studies in Epidemiology (STROBE) guidelines.

## TECHNIQUE

The skin incision used is a conventional 'V' or Brunner-type on the volar surface. The side chosen should correspond with the apex of the 'V' skin incision; this is to ensure vascularity of the skin flap is not compromised. The dissection proceeds through Grayson's ligament, where the next structure identified is the neurovascular bundle. This is protected, lateralised and the dissection then proceeds medially down to the level of the lateral aspect of the middle and proximal phalanges. At this point a longitudinal incision is made just dorsal to the origin of the A3 pulley (A), through periosteum and down

Received: Jul. 5, 2016; Revised: Jan. 13, 2017; Accepted: Jan. 20, 2017

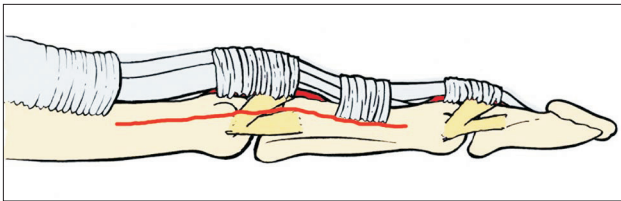
Correspondence to: Kalpesh R. Vaghela

Department of Trauma & Orthopaedic Surgery, Percivall Pott Rotation,  
Royal London Hospital, Whitechapel, London E1 1BB, UK

Tel: +44-7828950204

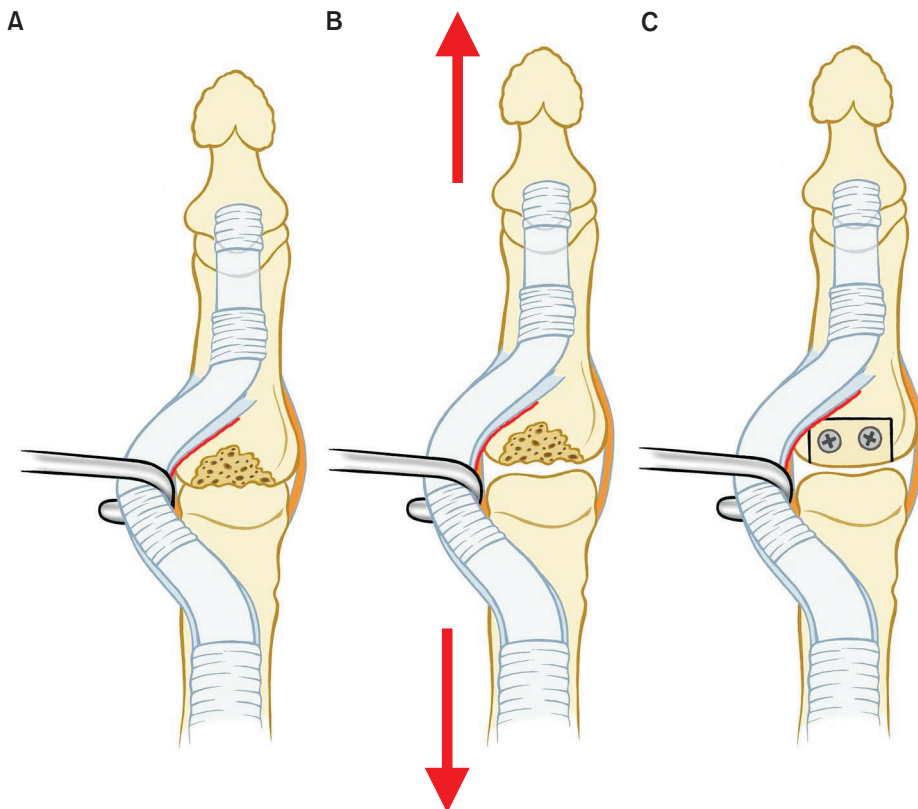
E-mail: kalpeshrvaghela@gmail.com

to bone and extended distally to the A4 pulley and proximally to the A2 pulley. The incision should pass through the accessory collateral ligaments, releasing it from the volar plate but spare the true collateral ligaments. Next, a small curved periosteal elevator is used to dissect and carefully lift off the palmar periosteum in one continuous layer from the original side to the opposite side, exposing the joint (Fig. 1). With retractors, the whole tendon pulley-volar plate complex is retracted to one side allowing access to the joint. Done correctly, there is no breach of the tendon sheath, neither is there damage to the true collateral ligaments, volar plate or pulleys (Fig. 2). With distraction (normally a pointed towel clip clamped around the distal phalanx tuft held by an as-



**Fig. 1.** Diagrammatic representation of approach to PIPJ. Line (red) indicates level of incision through accessory ligaments, in order to raise tendo-periosteal-volar plate unit.

sistant) and hyperextension of the joint (easily achieved with a small gauze roll placed underneath the finger), the fracture site can be viewed and prepared for the graft, in the conventional manner; we prefer using a small oscillating saw as opposed to rongeurs as a smooth, precise notch defect can be prepared. In most cases, we preserve as much of the radial and ulnar ‘pillars’ of cortical bone as possible, which then allows the graft to be ‘press-fitted’ into the notch before fixation. The defect is measured and a matching autograft harvested from the hamate. The graft is contoured to fit the defect exactly, matching the original tilt of the joint. As the joint surface is easily visible with the aid of distraction and hyperextension, the reconstruction can then be checked for any step-off. Fixation is via 2 screws angled in a volar to dorsal direction (1.0 mm or 1.3 mm), with temporary stability via a 0.9 mm Kirschner wire. Closure involves suturing the tendon pulley unit back down onto its corresponding periosteal layer (4.0 polydioxone). Post-operative care and therapy is identical to the standard hemi-hamate arthroplasty procedure. Informed consent was obtained from all patients and the study was approved by a local institutional review board.



**Fig. 2.** (A) Tendo-periosteal-volar plate unit retracted to one side to expose joint and fracture site, volar plate expressed in red; (B) Process of distraction and slight hyperextension (red arrows) to expose fracture site fully, ready for debridement with oscillating saw; (C) Autograft in-situ fixated with 2 1.0 mm screws.

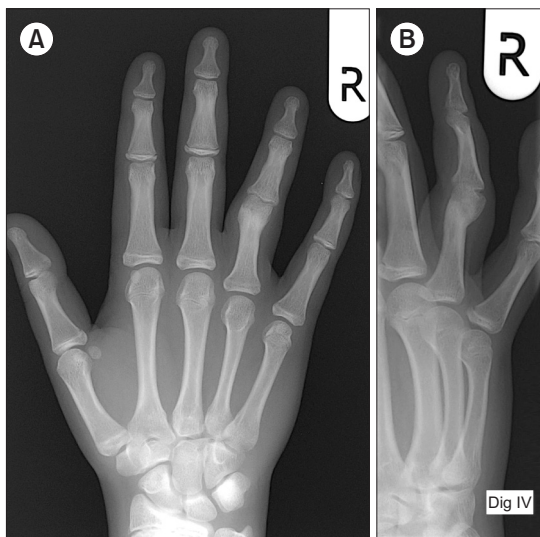
## RESULTS

Between the August of 2012 to the August of 2014, 4 cases with fracture dislocation of the PIPJ, with more than 50% (60–90) loss of articular cartilage of the base of the middle phalanx, underwent a hemi-hamate arthroplasty graft procedure, using the new approach to the joint. All patients were fully aware of the treatment aims and understood the risks and possible benefits and gave informed consent for the procedure. Average time of injury to surgery was 18 months (6–51) [all patients referred from other units]. The average follow-up period was 19 months (9–21). All measurements of range of motion and Visual Analogue Scoring (VAS) were analysed for statistical significance using a 2 tailed paired t-test. The preoperative flexion average was 35 (10–88)

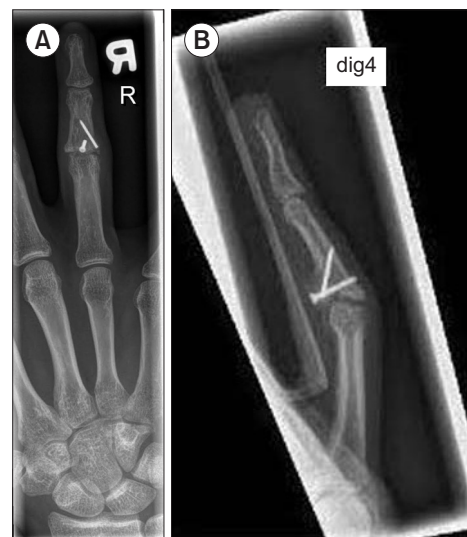degrees, which improved to 76 (50–102) degrees; extension lag was 11 (0–24) preoperatively, and postoperatively was 18 (0–38). Importantly, the total active range of motion (TAM) in the PIPJ improved from 26 (10–64), to 62 (26–102). Pain scores using VAS improved from 5 to 0. Patients all resumed their occupations. Radiographic evidence of full incorporation of the grafts was noted in each case (Fig. 3, 4). Summary of the patient's demographics and results are shown in Table 1.

## DISCUSSION

This new approach is a useful alternative technique for hemi-hamate arthroplasty as the intrinsic stabilising structures of the joint are not damaged, compared to conventional 'shot-gunning' of the joint. The latter tech-



**Fig. 3.** (A) Pre operative X-rays AP view. (B) Pre operative X-rays oblique view.



**Fig. 4.** (A) Post operative X-rays AP view. (B) Post operative X-rays lateral view.

**Table 1.** Patient Demographics and Outcome Measurements

Case	Age	G	Digit	Delay	F/up	% AS	VAS (pre/post)	DASH (pre/post)	Grip (pre/post)	PIPJ ext (pre/post)	PIPJ flex (pre/post)	TAM PIPJ (pre/post)	PRO
1	27	M	2	8	6	60	6/0		33	12/0	34/91	22/91	Good
2	18	M	4	7	10	70	5/0		46	24/0	88/102	64/102	Good
3	18	F	4	51	8	90	4/0		22	0/38	10/61	10/26	Good
4	19	M	4	6		70	5/0			0/20	10/50	10/30	Good
Ave	21			18		73	5/0			9/15	35/76	26/62	-
SD							0.8/0			11/18	36/24	26/40	-
<i>p</i>							0.001			0.72	0.02	0.06	-

G: gender, Delay: time of injury till reconstruction in months, F/up: followup in months, % AS: articular surface, VAS: visual analogue pain score, DASH: Disability of Arm, Shoulder & Hand Score, PIPJ: proximal interphalangeal joint, DIPJ: distal interphalangeal joint, PRO: Patient reported outcome, SD: standard deviation, *p*: *p* value, significant if *p* < 0.05.

**Table 2.** Comparison Table of Hemi-Hamate Arthroplasty Series

Study	Year	n	Delay/ days	F-up/ months	% AS	VAS	DASH (pre/post)	Grip strength/%	PIPJ AROM/ degrees	PIPJ lag/ degrees	Complications
Williams et al. <sup>1</sup>	2003	13	45	16	60	1.3	-	80	85	9	2x dorsal subluxation
Calfee et al. <sup>2</sup>	2009	22	141	54	62	1.4	5	95	70	19	1x severe flexion contracture; 1x bowstringing
Afendras et al. <sup>3</sup>	2010	8		60		1.0		91	67		
Lindenblatt et al. <sup>4</sup>	2013	10	93	8.6	64	-	-	95	71	6.5	2x tendon adhesion
Yang et al. <sup>5</sup>	2014	11	4	38	58	1.2	4.8	95	85	-	1x graft resorption
Barksfield et al. <sup>6</sup>	2015	7		3.5					65	20	
Goon et al. (2018)	2016	4	540	19	73	0		-	62 (26)*	14	

Delay: average time of injury till reconstruction, F-up: followup, % AS: average articular surface destroyed, VAS: visual analogue pain score, DASH: Disability of Arm, Shoulder & Hand Score, Grip strength: % compared to normal side, PIPJ: proximal interphalangeal joint, \*: preoperative range.

nique involves systematic release of the A3 pulley and opening up of the flexor sheath (reflected laterally and exposing the flexor tendons), the accessory collateral ligaments bilaterally, the volar plate distally (which is reflected proximally) and necessarily, the true collateral ligaments (limited release until joint can be hyperextended and dislocated). Predictably, damage of stabilising soft tissue structures may lead to complications such as post-operative joint scarring and contracture. Also, other issue reported include troublesome persistent dorsal subluxation resulting from inadequate volar plate repair, lateral subluxation of the joint secondary to collateral ligament instability (Table 2) (Williams et al.,<sup>1</sup> Calfee et al.,<sup>2</sup> Afendras et al.,<sup>3</sup> Lindenblatt et al.,<sup>4</sup> Yang et al.,<sup>5</sup> Barksfield et al.,<sup>6</sup> Saffar et al.<sup>7</sup>).

The technique of releasing all the palmar structures en bloc in one continuous layer is not new and has been previously described by Saffar in 1978 (Saffar et al.<sup>7</sup>), as a total anterior teno-arthrolysis (TATA). This radical method of joint arthrolysis is particularly useful for severe joint contractures following multiple surgeries as it allows the palmar structures to slide more proximally relative to the skeleton, allowing the joint to straighten. There are several differences with our approach. Firstly, our skin incision is a 'zig-zag' Brunner; with the skin flaps elevated separately from the palmar tissue (the original TATA uses midlateral incisions). Secondly, the neurovascular bundles are not included in the palmar flap but kept lateralised, thereby preventing any traction injury during retraction of the palmar flap to one side. Furthermore, the release is also limited to just beyond the PIPJ proximally and distally, whereas TATA involves an extensive release beyond the distal joint. Also, in our series, no true collateral ligament release was necessary

as arthrolysis was achieved just by the new approach to the joint. Importantly, the integrity of the tendon sheath is preserved, which means the risk of an iatrogenic cause for tendon adhesions is reduced.

Our preliminary results compare well with published series (see Table 2) and are encouraging, especially when our cases had a very much delayed time of presentation to surgery and a greater degree of articular loss. In fact, joint release was warranted in each case due to intrinsic tightness of the joint soft tissues, and was easily achieved as part of the new surgical approach; this was the original reason for adopting the new method. However, the preservation of stability of the joint and the potential decrease in new adhesions by this technique is the other major factor for adopting the technique. Patients treated early following injury tend to have better outcomes in regards to AROM and flexion contractures post-operatively (Calfee et al.<sup>2</sup>), presumably as there is less intraoperative scarring to contend with. Interestingly, even for some acute series, our results compare very favourably (Barksfield et al.<sup>6</sup>), although follow-up period was short in that series (3.5 months).

This pilot report does have limitations including a short follow-up period and small patient numbers. In this series, none demonstrated development of secondary osteoarthritis or resorption of the graft, but further follow-up is needed. Secondly, our cases all consisted of chronic cases (6 months or more), and makes comparison with current series difficult. Thirdly, we stress that this approach provides adequate access to the joint for the reconstruction, but the surgical view is still less than that achieved with the 'shot-gun' approach, and therefore this needs to be considered when choosing which approach to use.

In summary, this is a novel alternative technique to approach the PIPJ for hemi-hamate arthroplasty that allows for a controlled, method of arthrolysis, with minimal iatrogenic damage to the soft tissue stabilisers of the joint.

## REFERENCES

1. Williams RMM, Kiefhaber TR, Sommerkamp TG, Stern PJ. Treatment of unstable dorsal proximal interphalangeal fracture/dislocations using a hemi-hamate autograft. *J Hand Surgery Am.* 2003;28(5):856-65.
2. Calfee RP, Kiefhaber TR, Sommerkamp TG, Stern PJ. Hemi-hamate arthroplasty provides functional reconstruction of acute and chronic proximal interphalangeal fracture-dislocations. *J Hand Surg Am.* 2009;34(7):1232-41.
3. Afendras G, Abramo A, Mrkonjic A, Geijer M, Kopylov P, Taqil M. Hemi-hamate osteochondral arthroplasty for PIP Joint Fracture Dislocations: a minimum of 4 years follow-up. *J Hand Surg Eur.* 2010;35(8):627-31.
4. Lindenblatt N, Biraima A, Tami I, Giovanoli P, Calcagni M. Hemi-hamate autograft arthroplasty for acute and chronic PIP Joint Fracture Dislocations. *Handchir Mikrochir Plast Chir.* 2013;45(1):13-9.
5. Yang DS, Lee SK, Kim KJ, Choy WS. Modified hemi hamate arthroplasty technique for treatment of acute proximal interphalangeal joint fracture-dislocations. *Ann Plast Surg.* 2014;72(4):411-6.
6. Barksfield RC, Bowden B, Chojnowski AJ. Hemihamate arthroplasty versus transarticular Kirschner wire fixation for unstable dorsal fracture dislocations of the proximal interphalangeal joint in the hand. *Hand Surg.* 2015;20(1):115-9.
7. Saffar P, Rengeval JP. La te'noarthrolyse totale ante'rieure. *Annales de Chirurgie.* 1978;32(9):579-82.